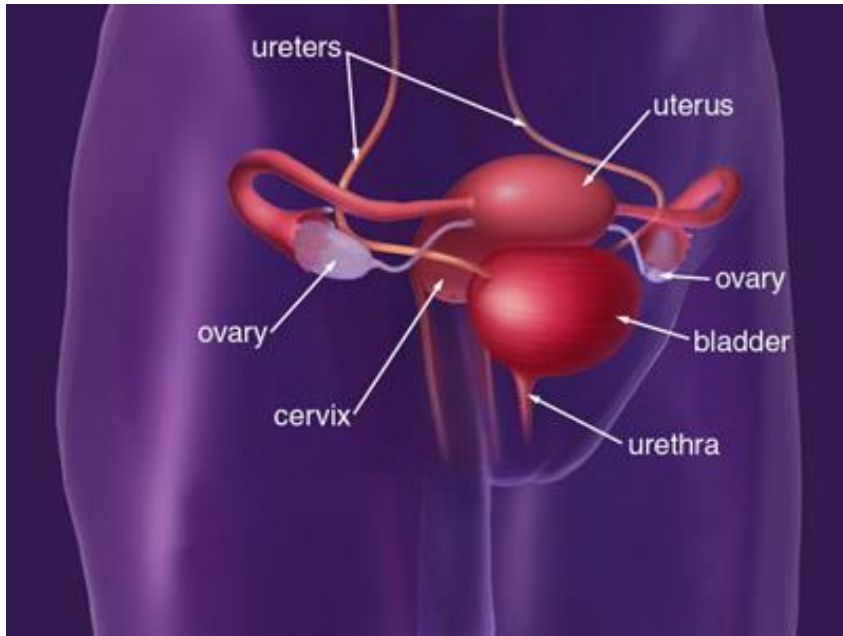


CASE PRESENTATION

Anja Løvvik, Dep of Urology/Pelvic Care Center



Woman born 1968



Picture from Memorial Sloan Kettering Cancer Center,
www.mskcc.org

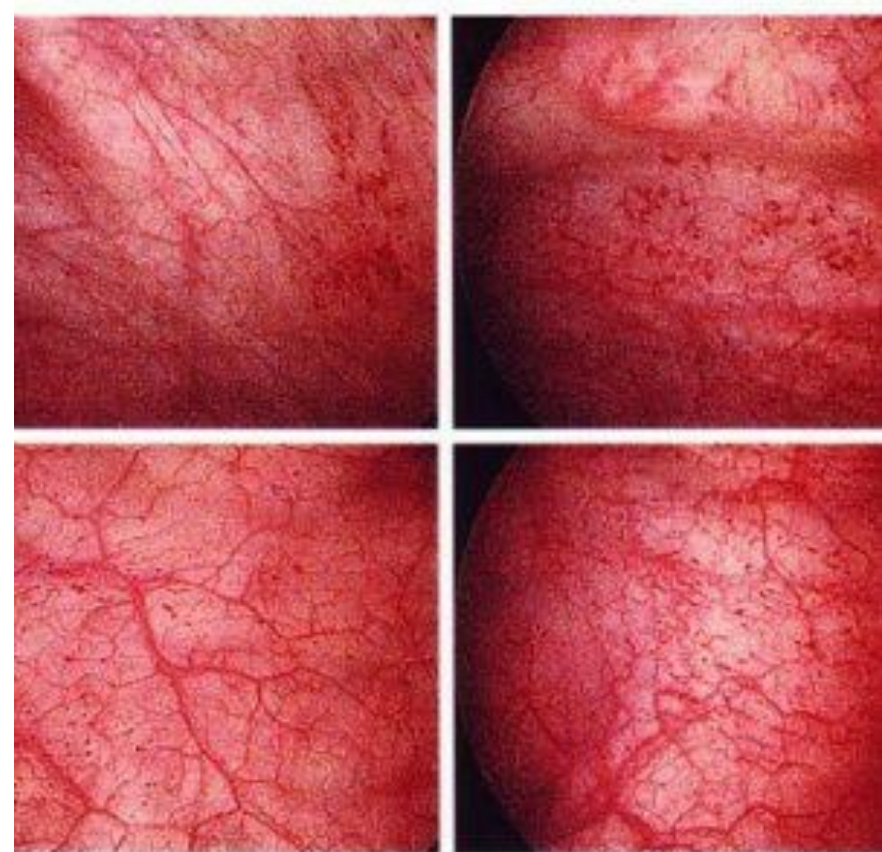
- Cervical cancer 2007
- Chemotherapy
- Pelvic radiation
- Oct 2011 Clavicular metastasis

Symptoms from 2011

- Pollacisuria
- Discomfort (not pain) before micturition, less symptoms after micturition
- Urgency incontinence
- Macroscopic hematuria

Examinations

- Cystoscopy: erythema, telangiectasies, no tumor
- Biopsy: chronic inflammation
- Urine cytology: no atypia
- CT scan with iv contrast negative



Picture from osvilt.com

Treatment

- Solifenacine (Vesicare®) stopped because of side effects (vertigo)
- Chondroitine sulfate (Uracyst®) instillations once a week
- Pain if >1 week between instillations
- Nov 2013 Sodium pentosane polysulfate
Pain free
- March 2016 pain free without medication
- If she gets pain again, we will start instillations
Elmiron works



Sodium pentosan polysulfate

- Binds to bladder mucosa
- Reduces bacterial adherence
- Dosage 100 mg x 3/d
- Side effects: Coagulopathy, thrombocytopenia, abdominal distension, nausea, alopecia, altered liver function, headache, vertigo, maculopathia
- Stop medication in pregnant/nursing women

