




**AGD 2016 BOSTON**  
REVOLUTIONARY CHANGES IN DENTISTRY

**John Sung, DDS, FAGD**

- Diplomate- American Board of Oral Implantology/Implant Dentistry
- Fellow - American Academy of Implant Dentistry



---

---

---

---

---

---

---

**AGD 2016 BOSTON**  
REVOLUTIONARY CHANGES IN DENTISTRY

**Reduced Vertical Dimension**

7/14/2016

---

---

---

---

---

---

---



**AGD 2016 BOSTON**  
REVOLUTIONARY CHANGES IN DENTISTRY

---

---

---

---

---

---

---

## Problems

- Lack of restorative space
- Breakage of fillings and prosthesis
- Poor esthetic

AGD 2016 BOSTON  
REVOLUTIONARY CHANGES IN DENTISTRY




---

---

---

---

---

---

---

---

## Causes

- Negligence of patients
- Failure to replace missing teeth
  - Tipping
  - Over eruption
  - Anterior attrition
  - Reduce vertical
- Oral habit
  - Bruxism

AGD 2016 BOSTON  
REVOLUTIONARY CHANGES IN DENTISTRY




---

---

---

---

---

---

---

---

## How to Handle?

---

---

---

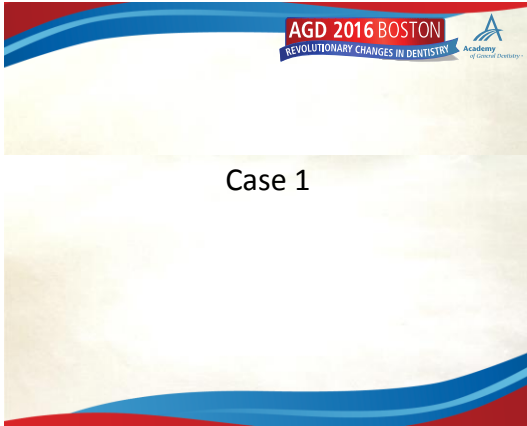
---

---

---

---

---




---

---

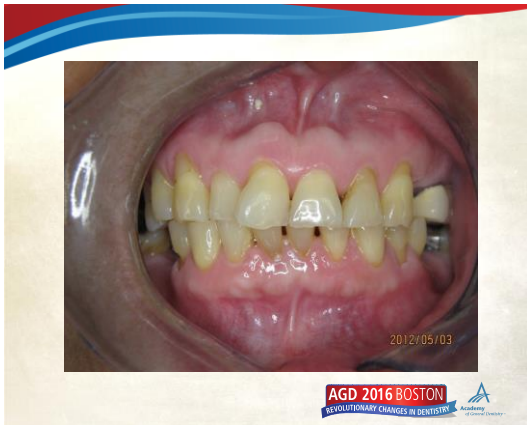---

---

---

---

---




---

---

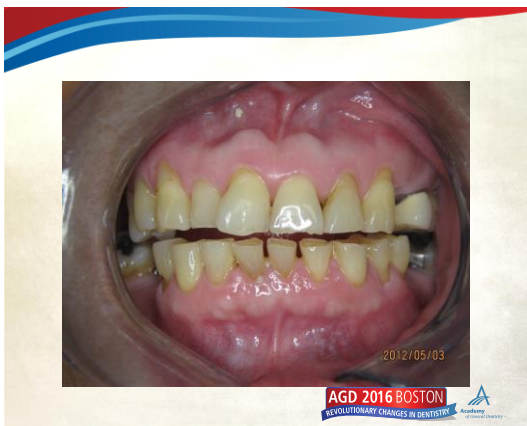---

---

---

---

---




---

---

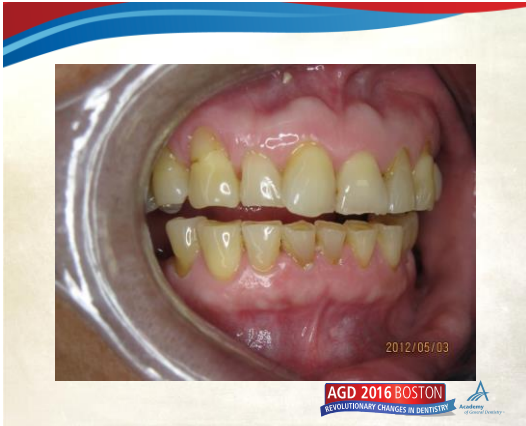---

---

---

---

---




---

---

---

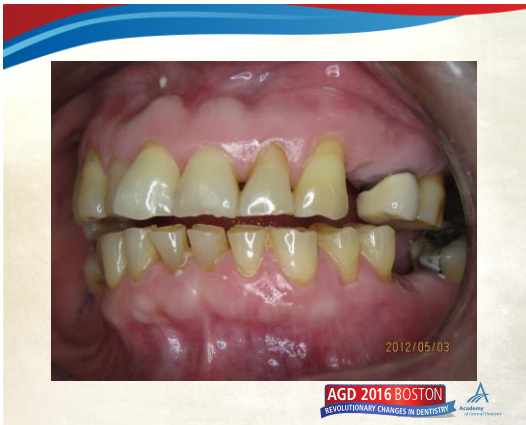---

---

---

---

---




---

---

---

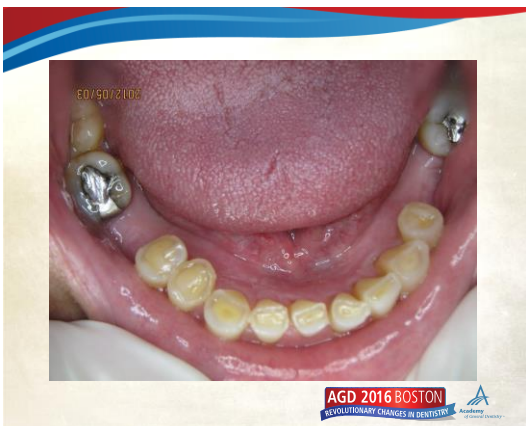---

---

---

---

---




---

---

---

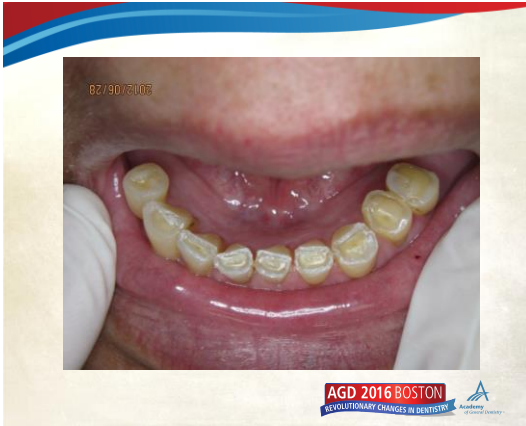---

---

---

---

---



---

---

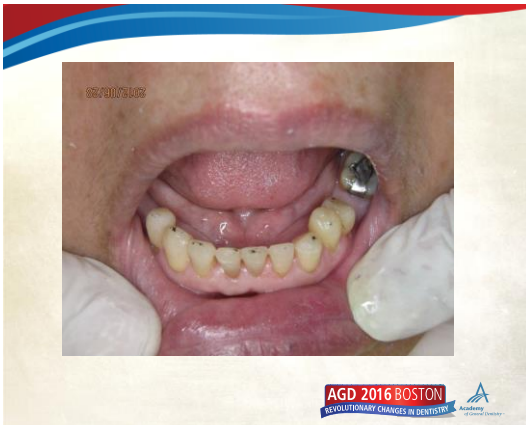---

---

---

---

---



---

---

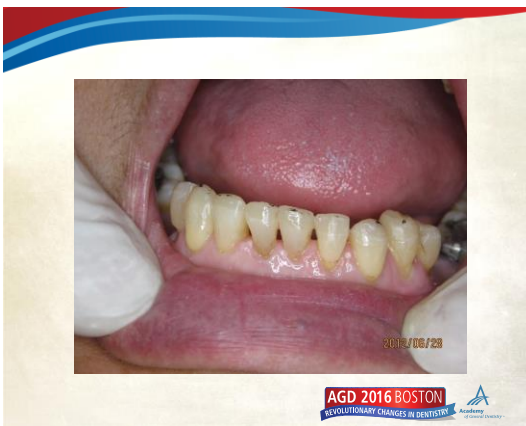---

---

---

---

---



---

---

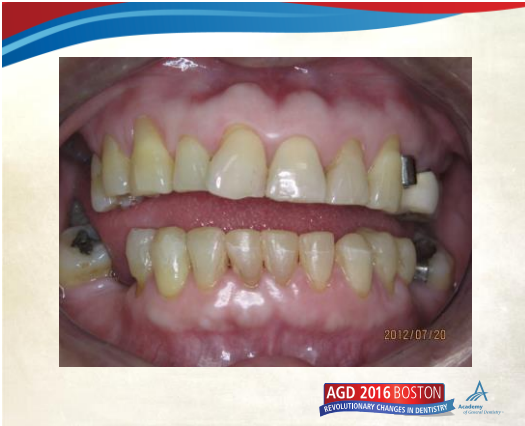---

---

---

---

---



---

---

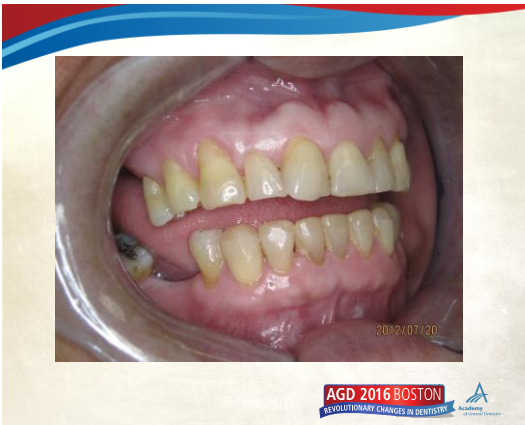---

---

---

---

---



---

---

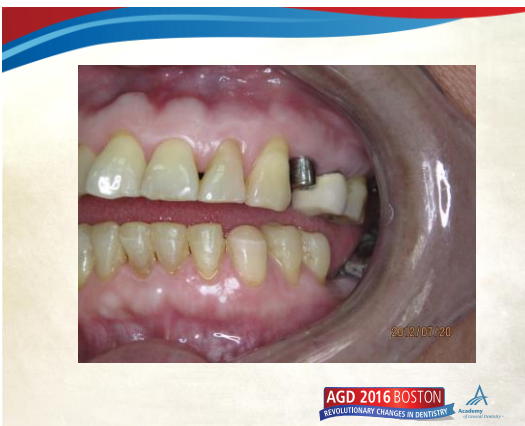---

---

---

---

---



---

---

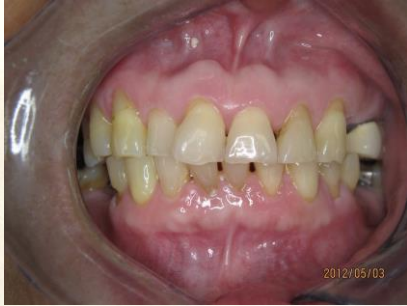---

---

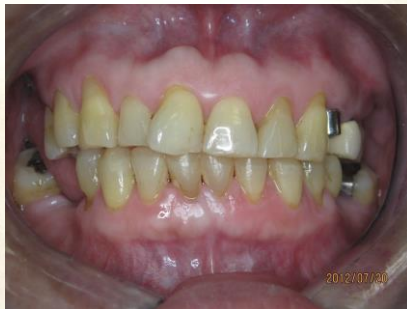---

---

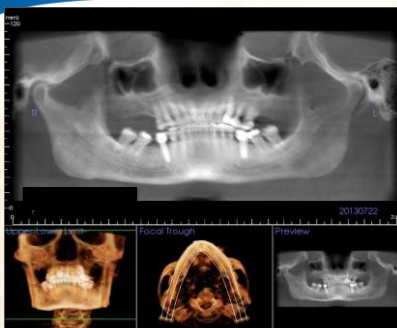---



AGD 2016 BOSTON  
REVOLUTIONARY CHANGES IN DENTISTRY



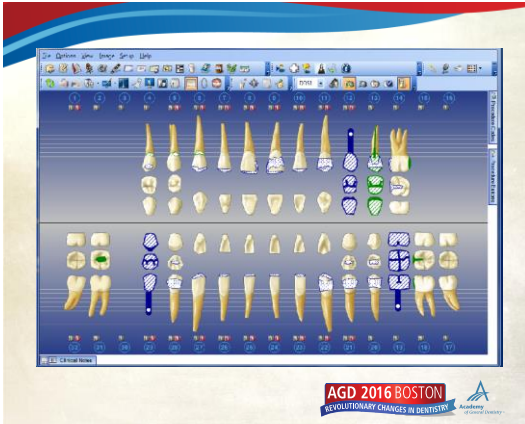AGD 2016 BOSTON  
REVOLUTIONARY CHANGES IN DENTISTRY



AGD 2016 BOSTON  
REVOLUTIONARY CHANGES IN DENTISTRY








---

---

---

---

---

---

---

---

## Summary

- What I did?
- Implants
- Restore lower Anteriors
- Increase OVD
- What did I not do?
- Line up #8, #9
- Restore upper molars on right side




---

---

---

---

---

---

---

---

## Case 2

---

---

---

---

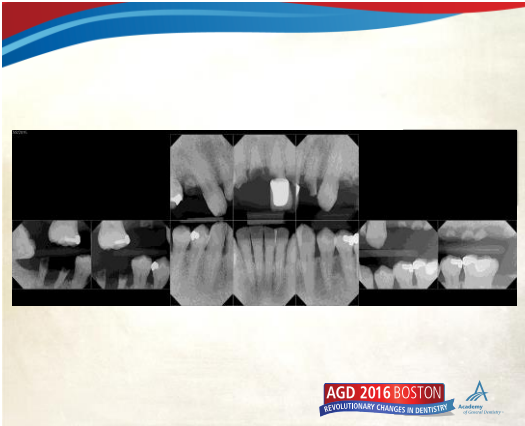---

---

---

---






---

---

---

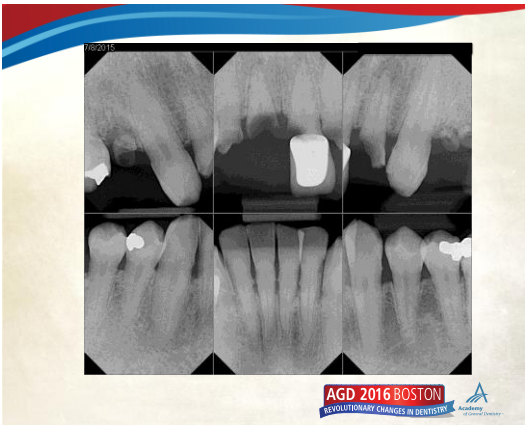
---

---

---

---

---




---

---

---

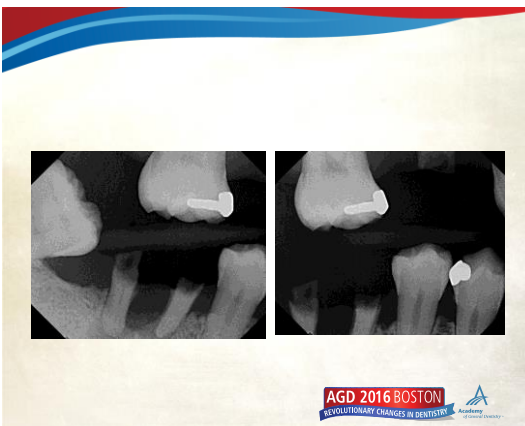
---

---

---

---

---




---

---

---

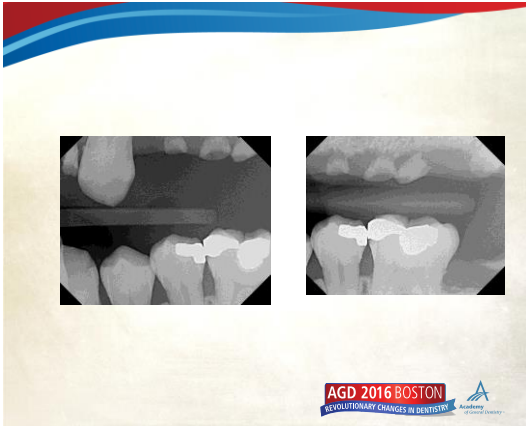---

---

---

---

---




---

---

---

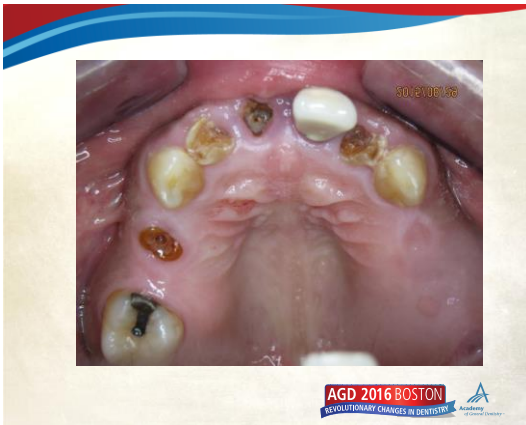---

---

---

---

---




---

---

---

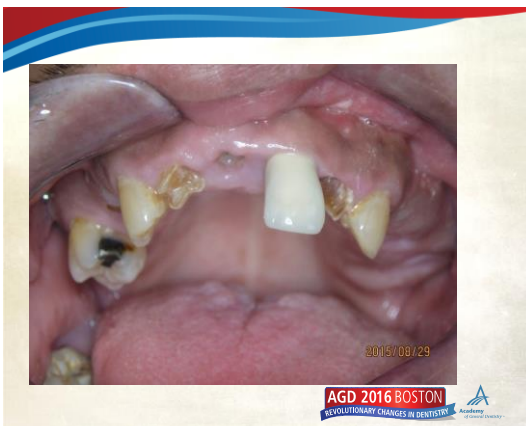---

---

---

---

---




---

---

---

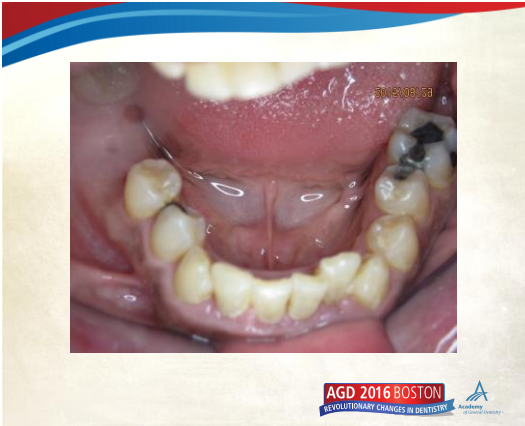---

---

---

---

---




---

---

---

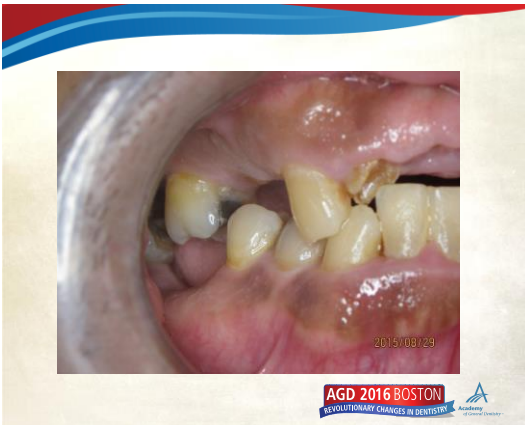---

---

---

---

---




---

---

---

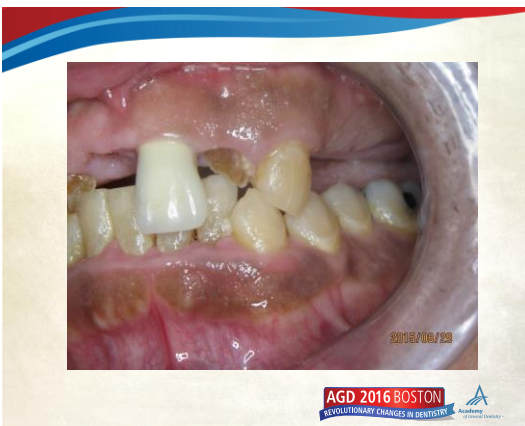---

---

---

---

---




---

---

---

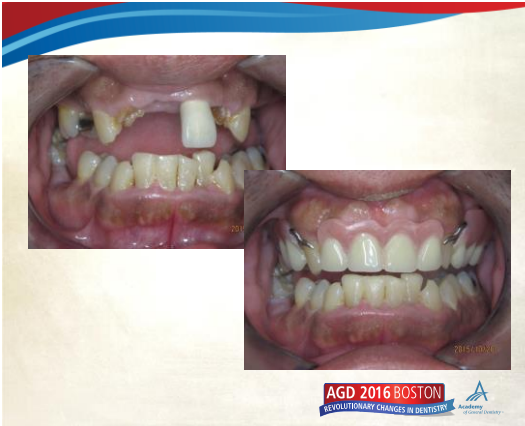---

---

---

---

---




---

---

---

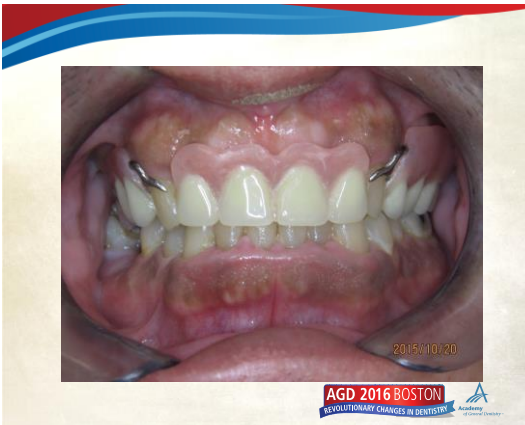---

---

---

---

---




---

---

---

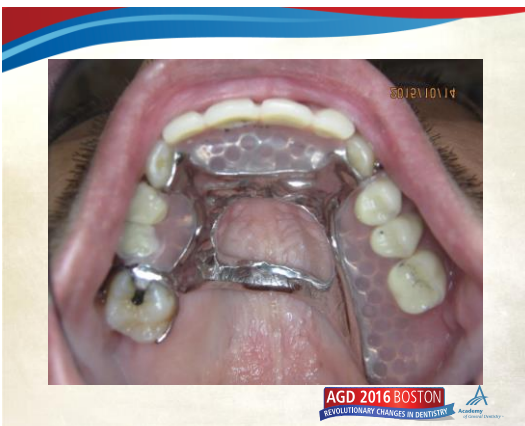---

---

---

---

---




---

---

---

---

---

---

---

---

## Summary

- What I did?
  - Extractions
  - Reduce and level lower incisal edge
  - Metal Frame PU
  - **Cingulum rests**
  - Increase OVD
- What did I not do?
  - Anterior bite plane to disclude the lower molars, allow them to erupt?

AGD 2016 BOSTON  
REVOLUTIONARY CHANGES IN DENTISTRY




---

---

---

---

---

---

---

---

## Case 3

AGD 2016 BOSTON  
REVOLUTIONARY CHANGES IN DENTISTRY




---

---

---

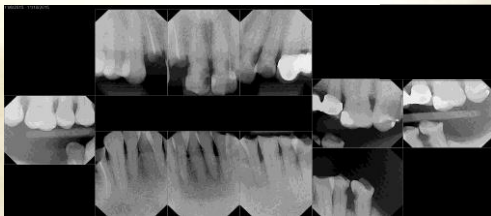
---

---

---

---

---



AGD 2016 BOSTON  
REVOLUTIONARY CHANGES IN DENTISTRY




---

---

---

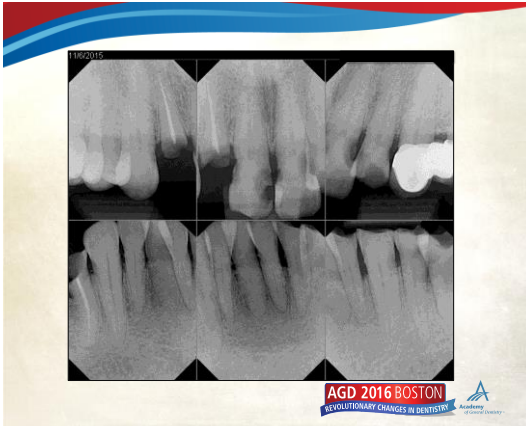---

---

---

---

---




---

---

---

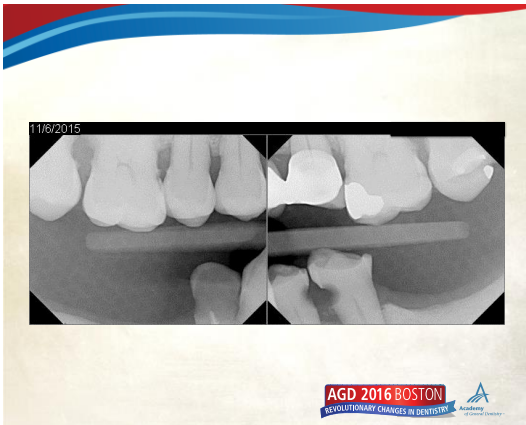---

---

---

---

---




---

---

---

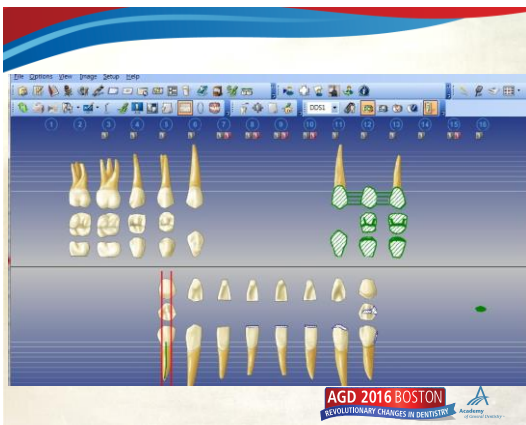
---

---

---

---

---




---

---

---

---

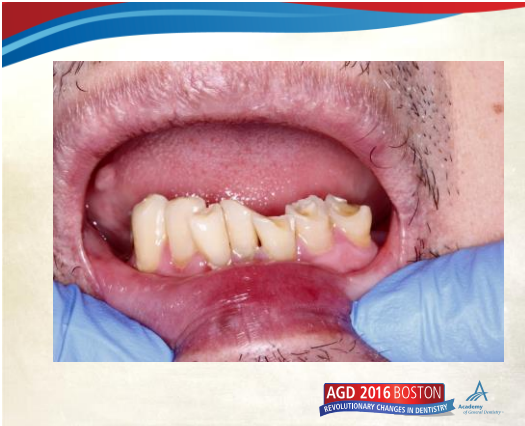---

---

---

---





---

---

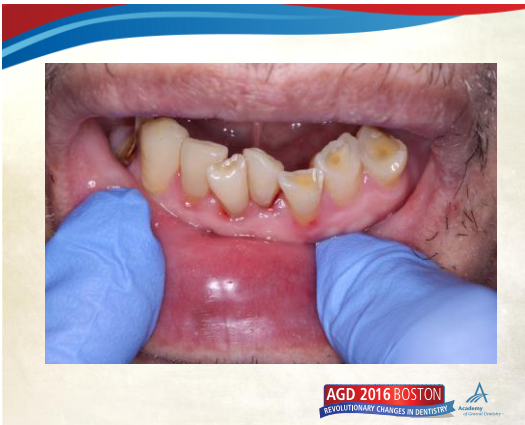---

---

---

---

---



---

---

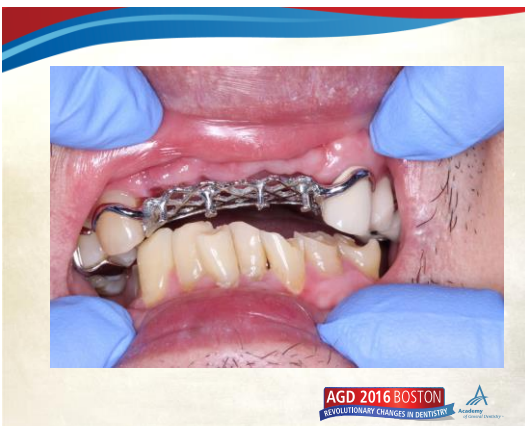---

---

---

---

---



---

---

---

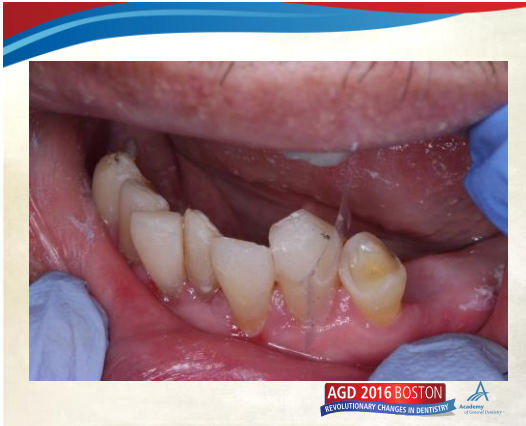---

---

---

---





---

---

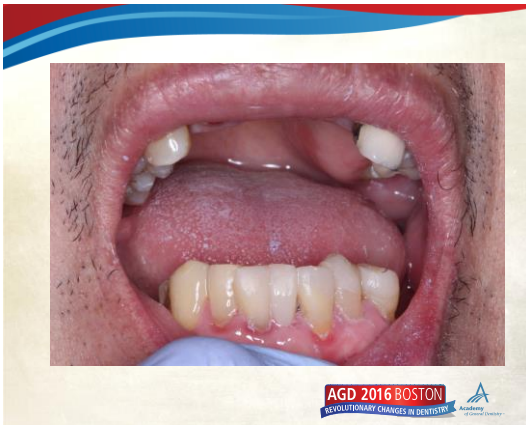---

---

---

---

---



---

---

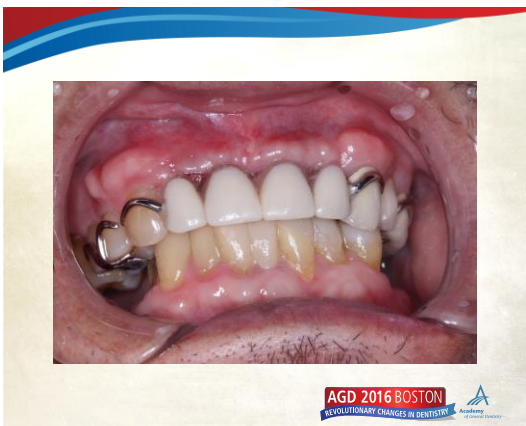---

---

---

---

---



---

---

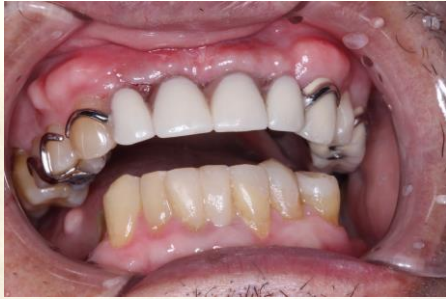---

---

---

---

---



AGD 2016 BOSTON  
REVOLUTIONARY CHANGES IN DENTISTRY

---

---

---

---

---

---

---

---

## Summary

- What I did?
  - Extractions
  - **Restore Lower Anteriors**
  - Metal Frame PU Denture
  - Increase OVD
  - TMJs in Centric Relation
- What did I not do?
  - Deal with Over-eruption on #3 and #4
  - Replace lower missing teeth

AGD 2016 BOSTON  
REVOLUTIONARY CHANGES IN DENTISTRY

---

---

---

---

---

---

---

---

## Problems

- Lack of restorative space
- Breakage of fillings and prosthesis
- Poor esthetic
- Create space
- Control occlusion
- Improve

AGD 2016 BOSTON  
REVOLUTIONARY CHANGES IN DENTISTRY

---

---

---

---

---

---

---

---

## How do I handle RVD?

- Eliminate unfavorable factors
- Improve existing condition
- Increase vertical dimension
- Eliminate CR-CO discrepancy

AGD 2016 BOSTON  
REVOLUTIONARY CHANGES IN DENTISTRY




---

---

---

---

---

---

---

---

The End

Thank you

AGD 2016 BOSTON  
REVOLUTIONARY CHANGES IN DENTISTRY




---

---

---

---

---


---

---

---

## John Sung, DDS, FAGD

- Diplomate- American Board of Oral Implantology/Implant Dentistry
- Fellow - American Academy of Implant Dentistry




---

---

---

---

---

---

---

---