



5th LUTD course, 2020

The price of the cure – cases

Henriette Veiby Holm

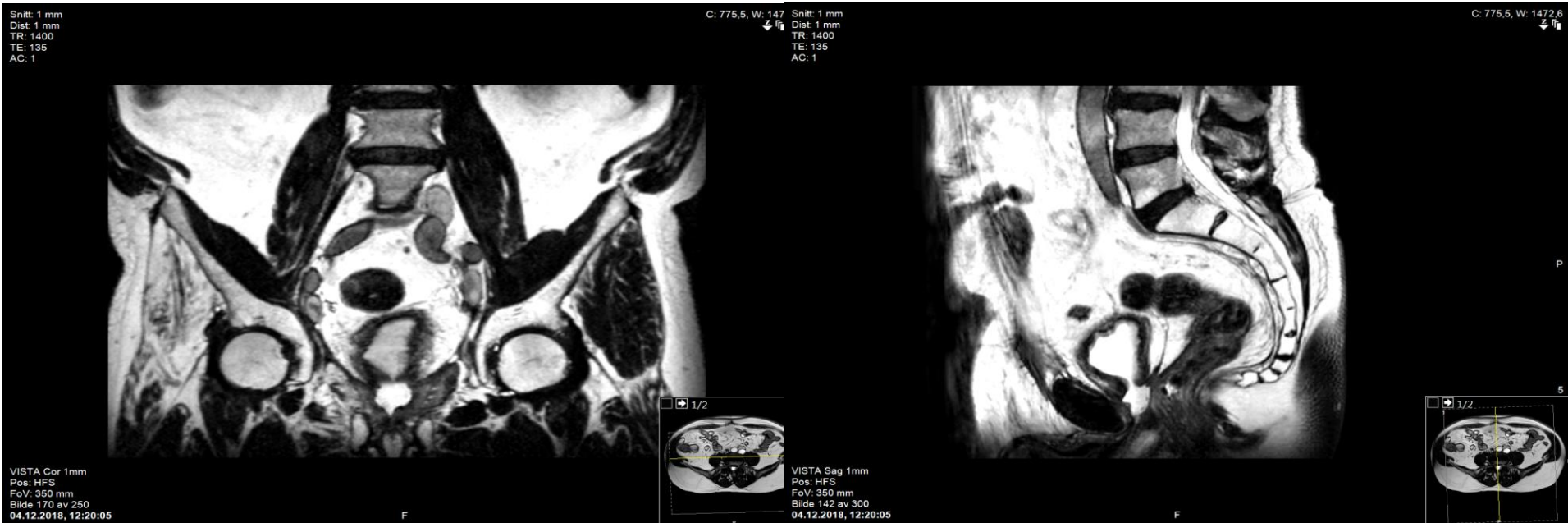Oddvar, male, born 1949

- Prostate cancer 2016
 - Radiation therapy and ADT
- PET 2017: recurrence (?)
 - Salvage prostatectomy
 - Complicated by
 - anastomotic insufficiency
 - stricture
 - complete urinary leakage
- Referred due to incontinence for artificial urethral sphincter...

Oddvar, male, born 1949

- Complete incontinence
- Otherwise «healthy»
- Cystoscopy/MRI/CT:
 - Stricture pars membranacea
 - Epithelialized cavity between sphincter and bladder neck
- Cystometry:
 - First desire to void at 50 ml
 - DO from 100 ml
 - Pdet 170 cmH₂O
- MUCG:
 - Infravesical cavity 2 x 2 cm
 - No fistula

Oddvar, male, born 1949



Oddvar, male, born 1949

Treatment?

1. Direct vision internal urethrotomy?
2. Botox?
3. Artificial urinary sphincter?
4. DVIU, Botox and AUS?
5. Urinary diversion?
6. Other reconstruction?

Oddvar, male, born 1949

Treatment:

Urinary diversion ad modum Bricker
without cystectomy

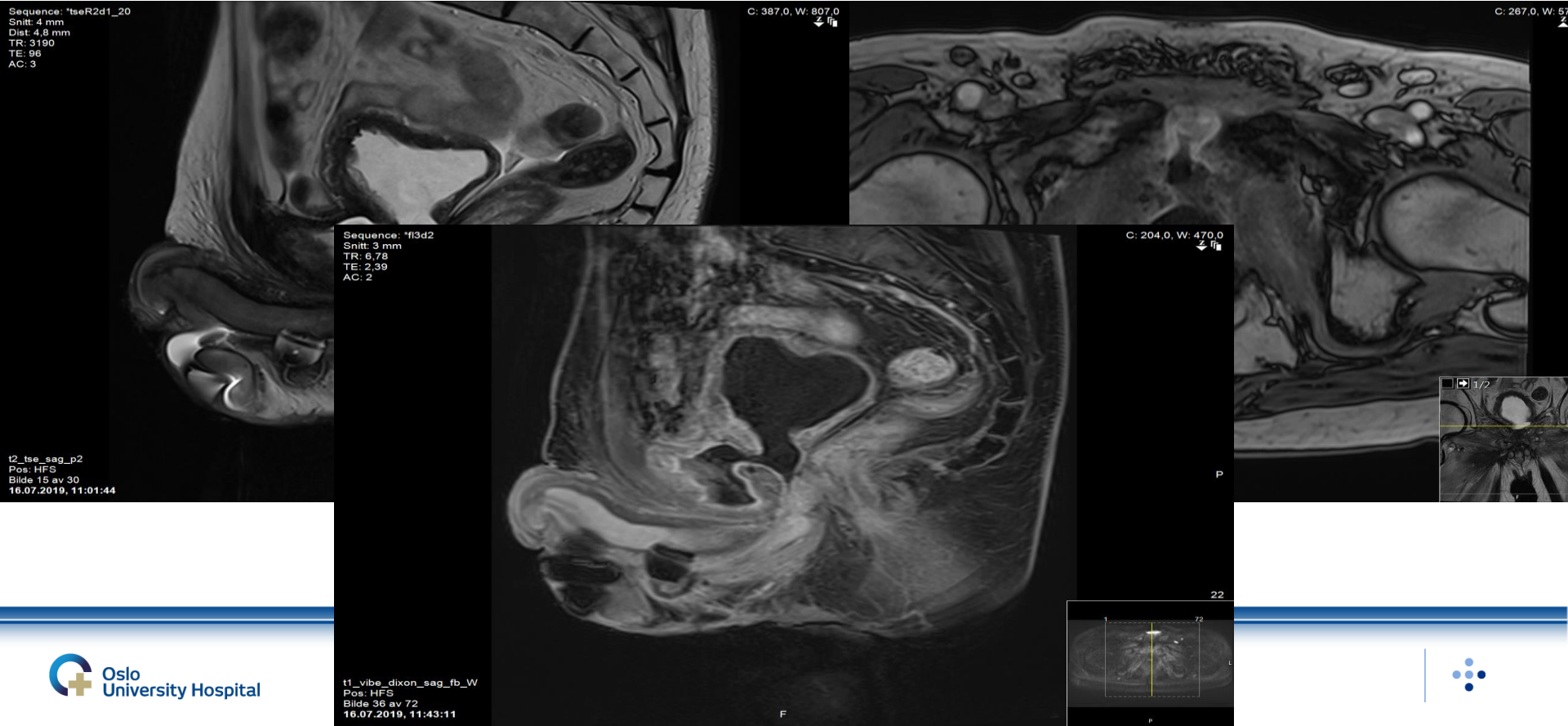
Bjørn, male, born 1944

- Prostate cancer 2001
 - Radiation therapy and ADT
- 2015: recurrence
 - Salvage prostatectomy
 - complicated by:
 - anastomosis insufficiency
 - lymphocele
 - urosepsis
- Infections
 - Fistulas from bladder neck to symphysis pubis
 - 2016: Osteomyelitis os pubis
 - 2017: Anastomosis stricture
 - Anastomosis/bladder neck resection
 - Complete incontinence

Bjørn, male, born 1944

- Complete incontinence
- 2018: Implanted AMS800...
- 2019: Worsening of osteomyelitis, big abscess from os pubis to right thigh drained
- Infected AMS800? No...
- Cystoscopy:
 - No erosion of AMS800
 - Stricture sphincter-anastomosis
- MRI:
 - abscess ramus inf. ossis pubis dxt
 - fistula from bladder neck → symphysis pubis → m. adductor

Bjørn, male, born 1944



Bjørn, male, born 1944

Treatment?

1. DVIU?
2. Drain abscess?
3. Remove artificial urinary sphincter?
4. Urinary diversion?
5. Other reconstructive surgery?

Bjørn, male, born 1944

Treatment:

- ✓ Removal of AMS800
- ✓ Cystectomy and excision of os pubis
- ✓ VRAM (Vertical Rectus Abdominis Musculocutaneous) flap for reconstruction
- ✓ Urinary diversion ad modum Bricker
- ✓ Treatment with Augmentin antibiotics for three months

Postprostatectomy incontinence

Not always feasible
to treat with AUS or sling...