

### Introduction and background information:

Plastic Bronchitis is a rare condition which affects both the adult and paediatric population. Within the paediatric population it is highly linked with post cardiac procedures, more so post Fontan. Roughly 4% of patients post Fontan procedure are said to be affected with plastic bronchitis (3,4)

Plastic Bronchitis can be related to abnormal lymphatic physiology and inflammation, and includes the formation of casts within the airways.

This can often lead to complete obstruction and high mortality rates (3)

There is limited research into plastic bronchitis due to its rarity.

Furthermore from a physiotherapy perspective there is little research to suggest best practice.

### Current Literature:

- Use of mucolytics including inhaled hypertonic saline/NaCl (3 or 7%) (1,2)
- Inhaled DNase (Dornase Alpha) (1,2)
- NAC (N-acetylcysteine) (1,2)
- 'aggressive physiotherapy'
- 'chest physiotherapy' (1,2,3,4)

The above has been mentioned in various research articles with respect to physiotherapy interventions, however no clear indication has been suggested with regards to what chest physiotherapy is, or a description of what techniques have been utilised.



### Case Study:

Patient X - 6 year old boy, underwent Fontan procedure 2 years prior to admission.

Presented with 1 day old cough, becoming increasingly short of breath and having difficulty breathing

Positive for rhino and enterovirus, and coronavirus (not COVID 19)

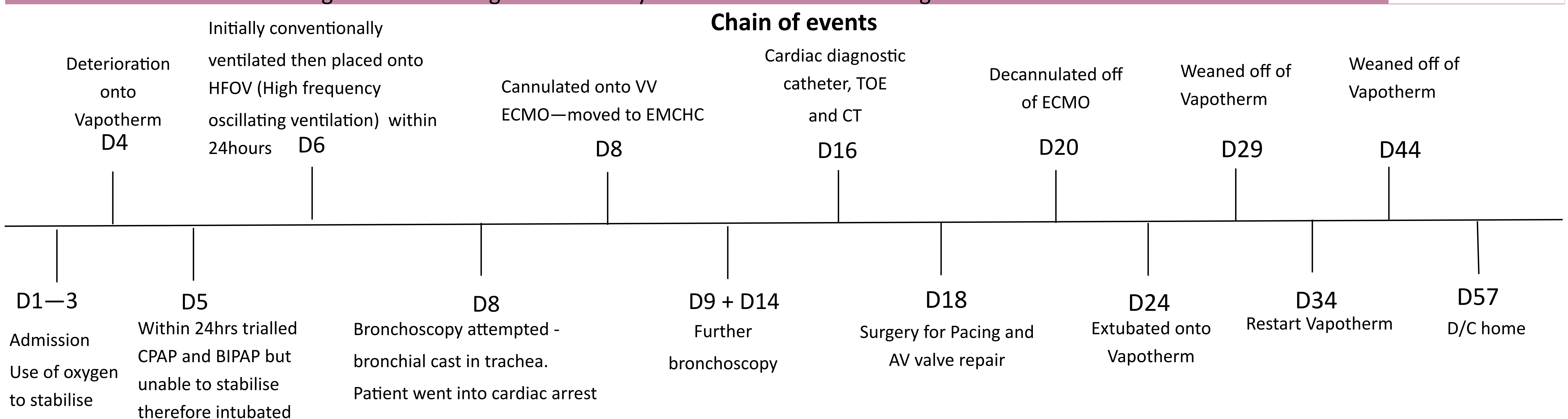
Overall spent 57 days as inpatient:

12 days on VV ECMO

4 bronchoscopy procedures with removal of casts

Surgery for pacing and AV valve repair

Discharged home making a full recovery and returned for ballooning of fenestration of Fontan



### During ECMO and Ventilated period

Regular physiotherapy - twice daily use of N-acetylcysteine (NAC), DNase and 7% hypertonic saline. DNase was provided 1 hour prior to physiotherapy intervention. Prior to physiotherapy, NAC was provided. During physiotherapy intervention the 7% was bagged through with a 3:1 stacked breath ratio, paired with quick release. Expiratory vibrations were provided on expiratory breaths. 8-10 cycles was completed with suction via ET tube with expiratory vibrations also. Yankauer suction to mouth, and soft tip to back of mouth also completed.

#### Self ventilating - prior to deterioration onto ECMO

- Good strong cough evident
- Encouraged mobility
- Bubble PEP attempted - patient not compliant
- 0.9% saline nebuliser started

#### Self ventilating - Post ECMO

- Rehabilitation - regaining mobility
- Continuing with N- acetylcysteine, 7% hypertonic saline nebulisers
- Bubble PEP

#### Prior to discharge

- Ensuring nebuliser routine established for home
- Community nurse referral—for provision of suction unit and nebuliser box

### Conclusion

- Use of DNase, N-Acetylcysteine and 7% hypertonic saline were effective in breaking down secretions
- Use of manual inflation bagging, stacked breaths and expiratory vibrations were also successful
- Use of clearway was suggested by respiratory team, however cardiac surgeons felt this was contraindicated following recent surgery

### Considerations

- Patient was on ECMO which provided the opportunity to complete physiotherapy interventions with fewer risks. Use of bronchoscopy to remove casts.
- Patient also underwent surgery to aid with overall function of heart and optimise pressures within the heart
- All interventions were used together therefore unable to determine which was most effective

### References

1. Brogan TV, Finn LS, Pyskaty DJ, Redding GJ, Ricker D, Inglis A et al. Plastic Bronchitis in Children: A case series and review of medical literature. *Pediatric Pulmonology* 2002;34:482-487
2. Singhi AK, Vinoth B, Kuruvilla S, Sivakumar K. Plastic Bronchitis. *Annals of Pediatric Cardiology*. 2015;8(3):246-248
3. Lis G, Chickocka-Jarosz E, Jednyak-Wasowicz U, Glowacka E. Add on treatment with nebulized hypertonic saline in child with plastic bronchitis after Glenn Procedure. *J Bras Pneumol*. 2014;40(1):82-85
4. Li Y, Willaims RJ, Dombrowski ND, Watters K, Daly KP, Irace AL. Current evaluation and management of plastic bronchitis in the pediatric population. 2020; 130. Available from: <https://doi.org/10.1016/j.ijporl.2019.109799>