



# Treatment of Non-Healing Pressure Ulcer Using a Chorion-Free Amniotic Membrane

## Allograft: a Case Report

Kyle Durfey, DPM, PGY-2, Jodi L. Walters, DPM, DABFAS

Southern Arizona Veteran Affairs Health Care System, Tucson, AZ



### Introduction

Amniotic membrane (AM) is a rich source of biologically active factors that play an important role in enhancement of wound healing and tissue regeneration. There have been many studies showing AM properties of anti-inflammatory effects, bacteriostatic, wound protection, decreased scarring, and pain reduction properties, as well as epithelialization initialization capacities. The many properties have been shown to be a benefit to heal wounds and have been shown to be successful in wound healing for many years. The purpose of this report is to evaluate the effectiveness of advanced wound care strategy of a chorion-free amniotic membrane allograft in the treatment of non-healing pressure ulcers.

### Methods

A 59-year-old diabetic patient with ID-DMII, PN, PVD, and depression underwent angioplasty for a pressure ulcer developed on the right lateral heel. After 5 weeks of angioplasty and standard wound care, the wound still persisted and remained fibrotic, thus another treatment modality was initiated using PalinGen® Hydromembrane, a chorion-free amniotic membrane allograft. Two applications of PalinGen® Hydromembrane were performed to treat the pressure ulcer over a period of 5 weeks.

Figure 1: After 1<sup>st</sup> application 28% decrease in area

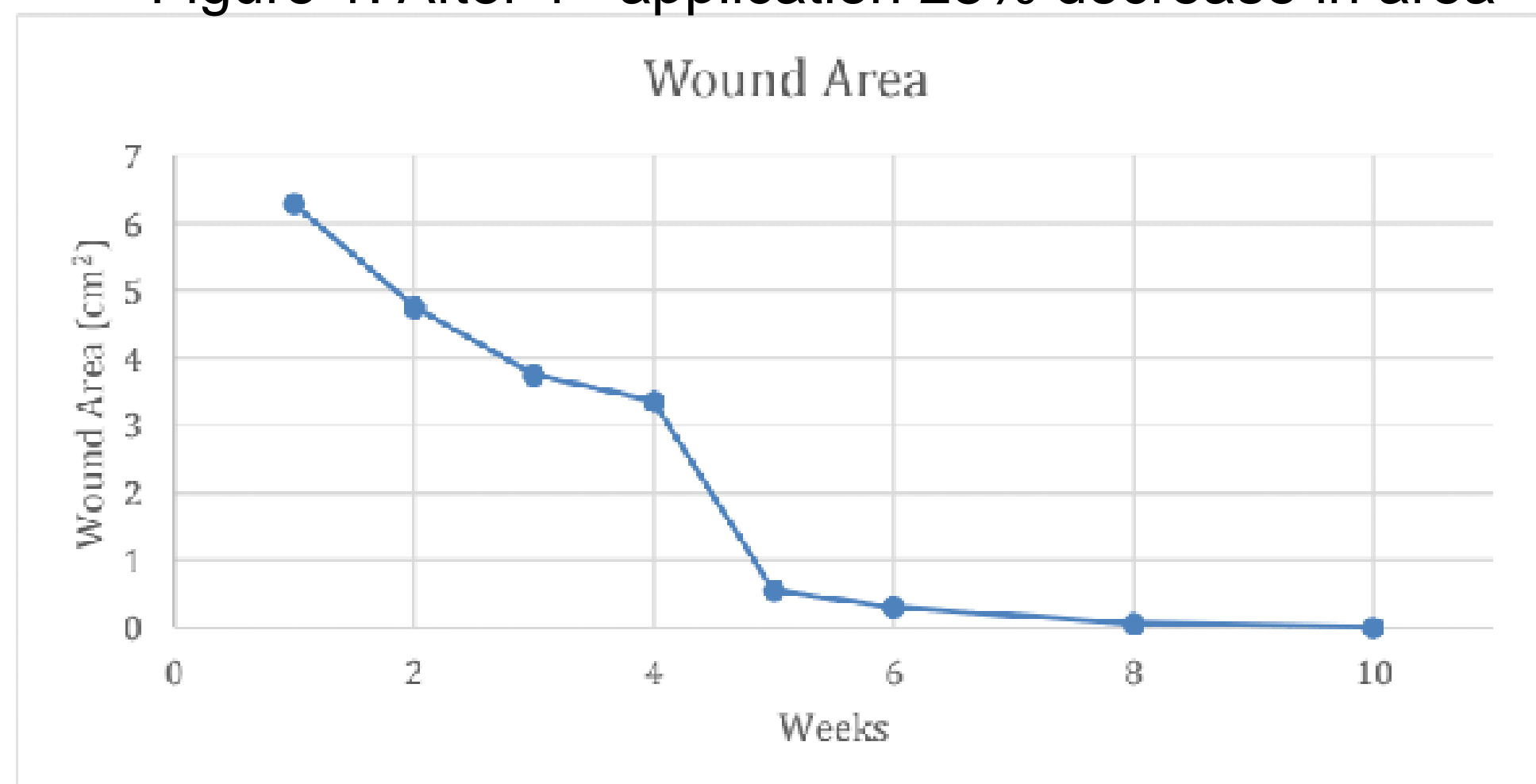


Figure 2: 1<sup>st</sup> visit after area was deeroofed and debrided with necrotic center noted but unstageable

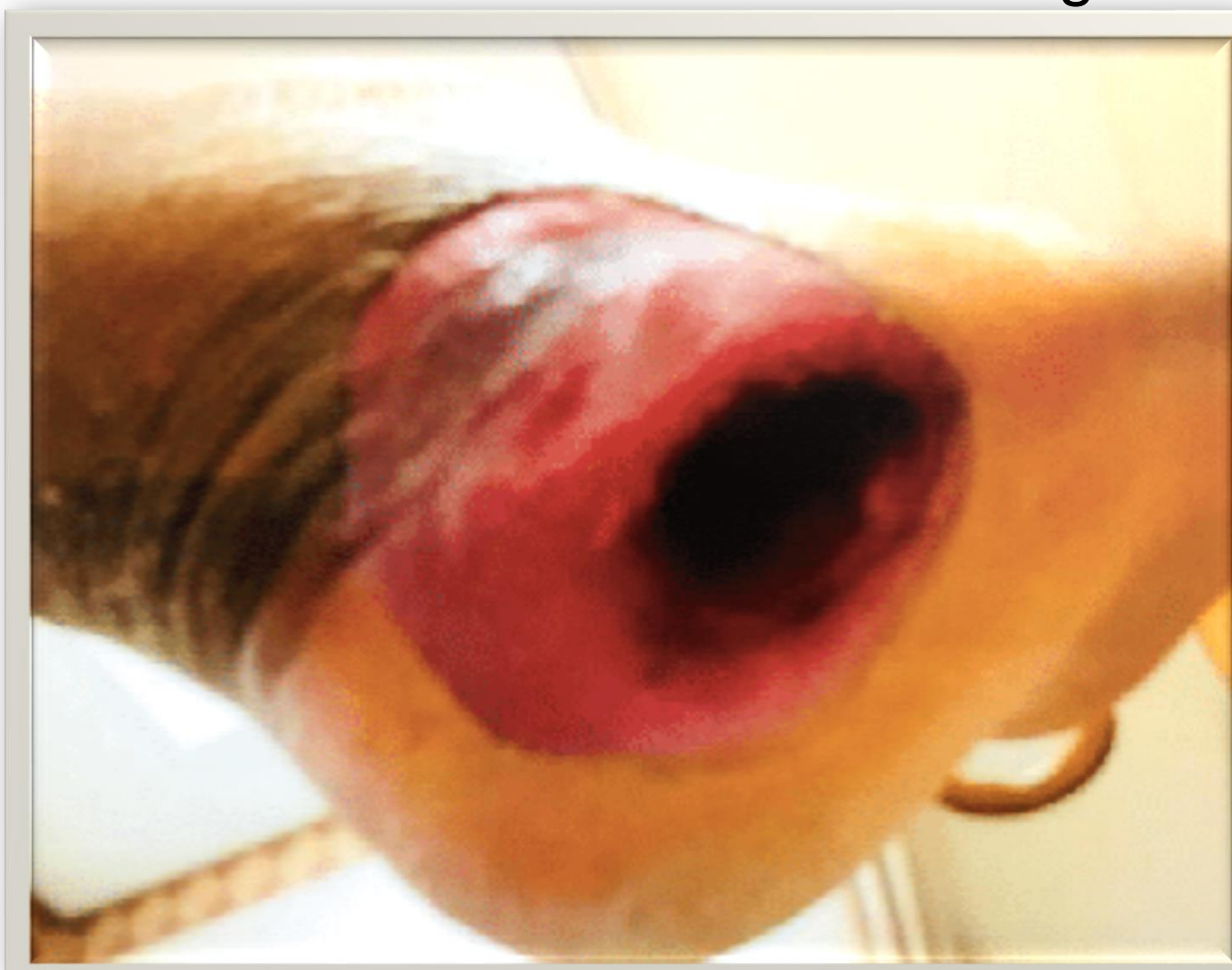
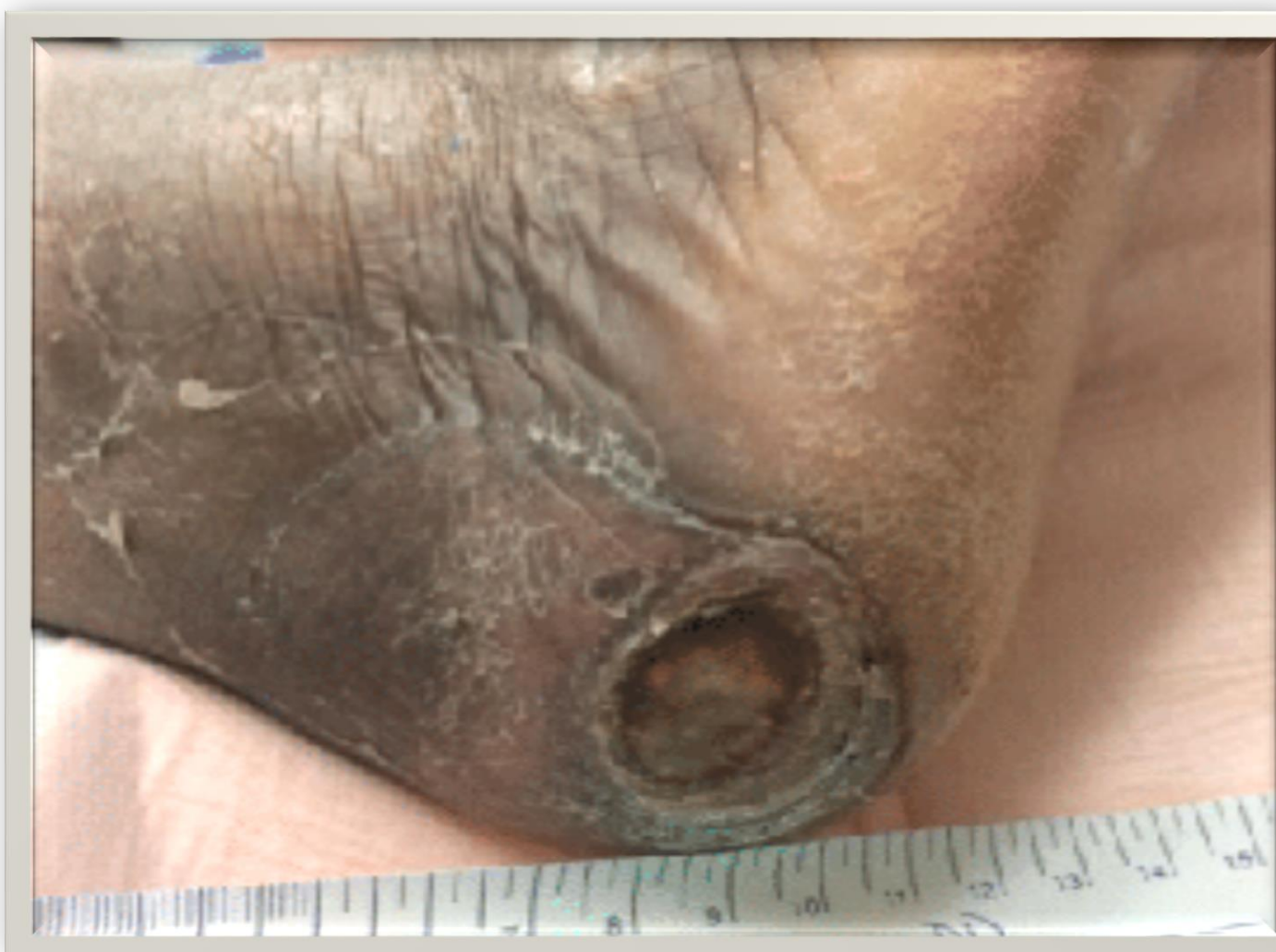

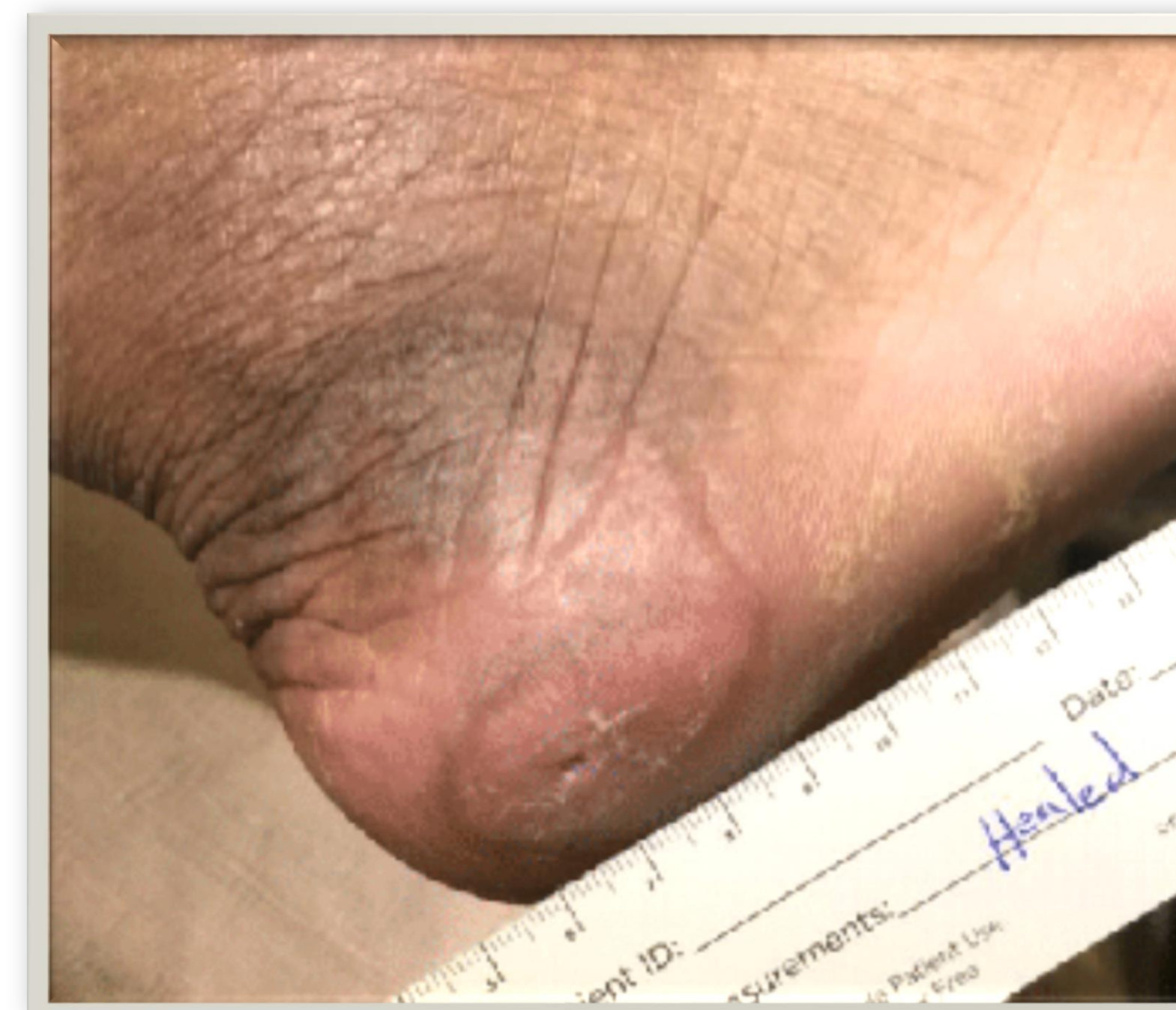Figure 3: after local wound care chronic wound only reduced 14%



### Results

At initiation of the PalinGen Hydromembrane® application, the wound had only decreased by 14% with local wound care post angioplasty. The wound was completely epithelized 5 weeks following PalinGen® Hydromembrane treatments. One week following the first application of PalinGen® Hydromembrane, the wound had decreased by over 28%. A second application was completed and continued dressings were performed weekly with calcium alginate and DSD. After only 2 applications and 5 weeks' time, the wound was completely epithelialized with mild overlying HPK. There were no adverse events or safety concerns associated with PalinGen® Hydromembrane treatments, and patient's wound site remains closed to date.

Figure 4: After 2 applications of PalinGen® Hydromembrane the wound epithelized and healed in less than 5 weeks



### Conclusions

The outcome of this study supports the use of a chorion-free amniotic membrane allograft as a safe and effective therapy to treat non-healing pressure ulcers, establishing PalinGen® Hydromembrane as a novel therapeutic option for managing complex pressure ulcers. The favorable outcomes in this study also suggests that PalinGen® Hydromembrane may be a successful alternative to the more expensive surgical approach.

### References

ElHeneidy H, Omran E, Halwagy A, Al-Inany H, Al-Ansary M, Gad A. Amniotic membrane can be a valid source for wound healing. *International Journal of Women's Health*. 2016;8:225-231. doi:10.2147/IJWH.S96636.

Didomenico, L., Orgill, D., Galiano, R., Serena, T., Carter, M., Kaufman, J., . . . Zelen, C. (2017). A Retrospective Crossover Study of the Use of Aseptically Processed Placental Membrane in the Treatment of Chronic Diabetic Foot Ulcers. *WOUNDS: A Compendium of Clinical Research and Practice*, 29(10). doi:10.25270/wnds/2017.10.311316

Zelen, C. M., Snyder, R. J., Serena, T. E., & Li, W. W. (2015). The Use of Human Amnion/Chorion Membrane in the Clinical Setting for Lower Extremity Repair. *Clinics in Podiatric Medicine and Surgery*, 32(1), 135-146. doi:10.1016/j.cpm.2014.09.002

Werber, B. (2015). Amniotic Tissues for the Treatment of Chronic Plantar Fasciitis and Achilles Tendinosis. *Journal of Sports Medicine*, 2015, 1-6. doi:10.1155/2015/219896

Tenenhaus, M. (2017). The Use of Dehydrated Human Amnion/Chorion Membranes in the Treatment of Burns and Complex Wounds. *Annals of Plastic Surgery*, 78. doi:10.1097/sap.0000000000000983

Zelen, C. (2013). An evaluation of dehydrated human amniotic membrane allografts in patients with DFUs. *Journal of Wound Care*, 22(7), 347-351. doi:10.12968/jowc.2013.22.7.347

### Acknowledgements

This material is the result of work supported with the resources and the use of facilities at the Southern Arizona VA Health Care System.

Clinical background and product support provided by AmnioTechnology, LLC